

IMPORTANCE OF TONGUE IN RETENTION AND STABILITY OF COMPLETE DENTURES

Natasha Stavreva

Faculty of Dentistry, Skopje, Department of Prosthodontics, University “St. Cyril and Methodius”-
Skopje, N. Macedonia, natasha_stavreva@yahoo.com

Abstract: Tongue is muscular organ of the body located in floor of mouth and is anchored to hyoid bone, mandible, soft palate, pharyngeal wall and styloid process in the oral cavity. It is readily associated with numerous vital oral and maxillofacial functioning, such as taste, mastication and deglutition, and takes part in sucking, swallowing, speech, receiving food into mouth, and articulation. It is important to understand the anatomy, size, position and classification of the tongue and surrounding musculature without which it is impossible to achieve proper retention and stability of the complete denture. This paper covers the various factors of the influence of the tongue in securing retention and stability of the complete dentures and ways to overcome these difficulties.

Keywords: tongue, retention, stability, complete dentures

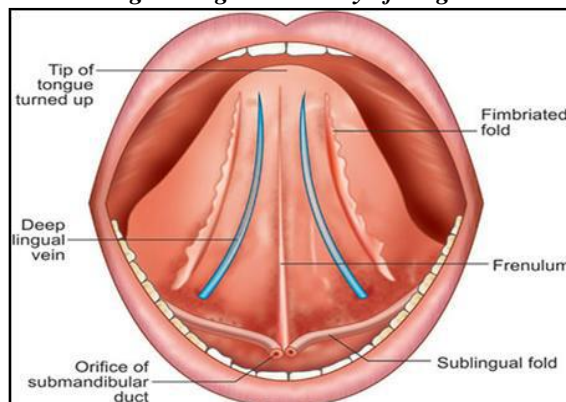
1. INTRODUCTION

Tongue is muscular organ which is anchored to hyoid bone, mandible, soft palate, pharyngeal wall and styloid process in the oral cavity. It is readily associated with numerous vital oral and maxillofacial functioning, such as taste, mastication and deglutition, and takes part in sucking, swallowing, speech, receiving food into mouth, and articulation. Lack of any mentioned above activity may lead to severe impairment in socialization and patient's quality of life. Also, tongue plays an important role in formation and production of effective speech by facilitating formation of consonants and vowels by contacting specific part of the teeth, alveolar ridge or hard palate. [1]

Anatomy of tongue

The root of the tongue is attached to the hyoid bone and the mandible. The dorsum of the tongue is divided into an anterior 2/3rd and posterior 1/3rd, which are separated by a faint V - shaped groove called as sulcus terminalis. Hence the anterior part is called the presulcal or oral or papillary part and the posterior part is called the post sulcal or pharyngeal or glandular part. The limbs of the V shaped sulcus run anteriolaterally and form a median foramen caecum (from where the thyroid has its origin) and ends with the palatoglossal arch on either side. The tip of the tongue forms anterior free end and lies behind the maxillary incisors at rest. The ventral surface of tongue is smooth and purplish in color and show a median mucosal fold known as frenulum linguae. Deep lingual veins lie laterally to frenulum linguae and fringed mucosal ridge known as plica fimbriata lies adjacent to it. [2] (Fig. 1)

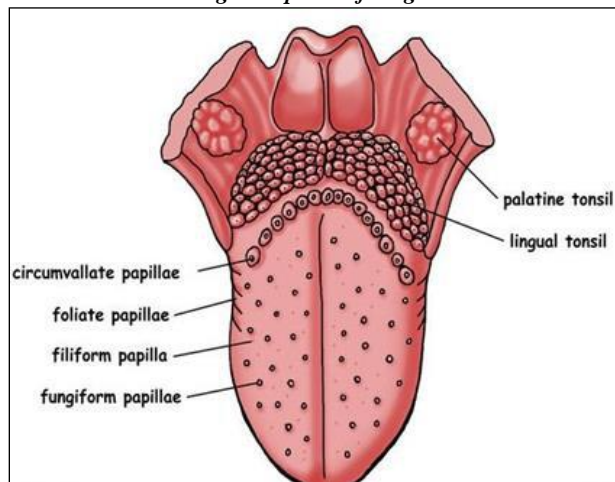
Fig. 1 Lingual anatomy of tongue



Papillae of tongue

These are small finger like projections of lamina propria that elevates the epithelium. They are predominantly found on the anterior two third of the tongue giving it, its characteristic roughness. These are of four types: circumvallate, fungiform, filiform and foliate papillae. Circumvallate papillae being the largest of all are seen immediately in front of sulcus terminalis whereas others are located around the tip and margins of the tongue. (Fig. 2)

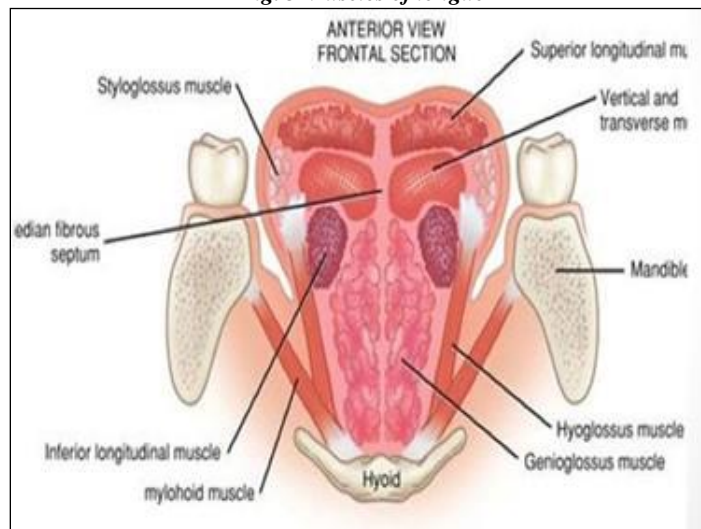
Fig. 2 Papillae of tongue



Muscles of tongue

A median fibrous septum divided the tongue into right and left halves. Each half contains two sets of muscles, which are intrinsic and extrinsic. The *intrinsic muscles* are seen in the upper portion of tongue and is attached to submucous fibrous layer and the median fibrous septum. There are four paired intrinsic muscles and are named by the direction in which they travel: The Superior Longitudinal, Inferior Longitudinal, Transverse muscle and Verticalis. These muscles alters the shape and size of the tongue. The *extrinsic muscles* are four in number, and connects tongue to mandible via Genioglossus, to hyoid bone via Hyoglossus, to styloid process via Styloglossus and the palate via Palatoglossus. These are commonly associated with retraction, elevation and depression of the tongue surface. (Fig. 3)

Fig. 3 Muscles of tongue



Movements of tongue

The tongue is used in sucking, chewing, swallowing and speaking, pursing and licking of lips. The intrinsic muscles alters the shape of the tongue whereas the extrinsic muscles stabilizes the organ by their contraction and alters its position and shape too. [3]

Alteration of shape

The transverse muscle narrows the tongue and elongates it. With simultaneous contraction of the verticalis muscle, the convexity of tongue is flattened and broadened. The contraction of longitudinal fibers of inferior longitudinal muscle makes the tongue concave from front to back while the contraction of the vertical fibers produces a midline groove helping in first stage of swallowing.

Alteration of position

Styloglossus retracts the tongue. Hyoglossus draws the sides of the tongue downward. The mylohyoid muscle alters the position of tongue. The lowest fibers of genioglossus contracts the back of tongue and it is extruded. [4] (Table 1)

Table 1 Location and Effect of the Musculature Limiting the Lower Denture Space

Dislocating muscles	Fixing muscles
Vestibular	
Massater	Buccinators
Mentalis	Orbicularis oris
Incisivuslabiiinferioris	
Lingual	
Internal pterygoid	Genioglossus
Styloglossus	Lingual longitudinal
Palatoglossus	Lingual transverse
Mylohyoid	Lingual vertical

Innervation of tongue

In the anterior 2/3rd, the lingual nerve, a branch of the mandibular nerve is responsible for general sensation while the chorda tympani nerve a branch of facial nerve is responsible for taste sensation. The posterior 1/3rd of the tongue is supplied by the glossopharyngeal nerve whereas the posterior-most part of tongue is innervated by Internal Laryngeal branch of the Vagus nerve.

Arterial and venous drainage

Major portion of the tongue is supplied by the lingual artery, a branch of the external carotid artery except the root of the tongue which is supplied by tonsillar artery, a branch of the facial artery. Deep lingual vein drain the tongue. It starts from the tip on inferior surface of tongue, near anterior border of hyoglossus, joining the sublingual vein and forms vena commitans nervi hypoglossi which further drains into facial vein and internal jugular vein.

Lymphatic drainage

Submental and submandibular lymph nodes drain the tip and the anterior two thirds of the tongue respectively whereas the posterior one third is drained by juglo-omohyoid lymph nodes. The upper deep cervical lymph nodes drain the posterior most area of tongue.

2. MANIFESTATIONS OF SYSTEMIC DISEASES ON TONGUE

Tongue is examined carefully for various systemic diseases for its oral manifestations. In case of Iron deficiency anaemia it represents as Atrophic glossitis, due to flattening of the papillae on the dorsum of the tongue accompanied with a tenderness or a burning sensation. While in Pernicious Anemia it appears as “Magenta tongue” due focal or diffuse erythema of the tongue and mucosal atrophy. [5]

In autoimmune diseases like Sjogren Syndrome its appears “bald” or even “cobblestone-like” tongue due to atrophy of the papilla. While in Kawasaki Disease, its seen as Strawberry tongue due to swelling of papillae on the surface of the tongue and intense erythema of the mucosal surfaces. In Scleroderma it appear smooth and can lose mobility. In Systemic Lupus Erythematosus it appears with Multiple granulomatous-appearing ulcerations on the tongue dorsum.

In endocrinal disorders like Diabetes Mellitus it is seen as central papillary atrophy of the tongue dorsum. In viral diseases like HIV- AIDS it appears in form of Oral hairy leukoplakia which is categorized as a white lesion which is usually present on the lateral surface of tongue. [6]

3. FACTORS OF RETENTION AND STABILITY

The factors of retention can be briefly divided into: [7]

- Physical
- Biological
 - Orofacial musculature
 - Neuromuscular control
 - Intimate Tissue contact
 - Border seal
- Mechanical

- Surgical
- Psychological

The factors of stability can be grouped into: [8]

- The relationship of external surface and the periphery of the denture to the surrounding orofacial musculature
- Relationship of the denture base to the underlying tissues
- Relationship of opposing occlusal surfaces.

Let us consider the orofacial musculature and their relationship with external surface and periphery of the dentures as influencing retention and stability. The most common complaint of complete denture patients concerns the loose mandibular denture. It is mainly due to the patient's lack of understanding to the special problems associated with the mandibular denture. Patients should be educated to the three basic handicaps associated with the mandibular denture. [9,10]

4. CLASSIFICATION OF TONGUE AND ITS PROSTHETIC IMPORTANCE

A) Functional tongue classification

Functional tongue classification according to degree of activity by Barnett Kessler was done into four types based on working range of tongue: [11]

The Occupational tongue: Apply to those people whose activities require increased tongue action, such as jurists, teachers, lecturers, preachers, musicians.

The Still tongue: Also called Passive tongue. Have limited tongue activity. This could be due to injury, deformity etc., such as ankyloglossia.

The Normal tongue: It is of prosthodontist's delight. Tongue exhibit normal function and range of movements.

The Habitual tongue: It refers to the disturbing powerful movements of the tongue developed due to habit. Base of the tongue is thick and powerful and imposes dislodging forces on the denture.

According to this author, tooth arrangement should be done in a manner so that it does not affect the functioning of the tongue. The base of the tongue is frequently "hooked" by the lower second molars resulting in unstable lower dentures. Therefore, lower second molars in complete dentures should be arranged without hindering the tongue movement.

B) Classification of tongue position according to Wright (Table 2)

Normal	The tongue fills the floor of the mouth; and is confined by the mandibular teeth. The lateral borders rest on the occlusal surfaces of the posterior teeth and the apex rests on the incisal edges of the anterior teeth. There is no aberration in tongue size or activity.
Class I	Retracted: The tongue is retracted. The floor of the mouth; pulled downward is exposed back to the molar area. The lateral borders are raised above the occlusal plane and the apex is pulled down into the floor of the mouth. Class I provides the best prognosis.
Class II	Retracted: The tongue is very tense and pulled backward and upward. The apex is pulled back into the body of the tongue and almost disappears. The lateral borders rest above the mandibular occlusal plane. The floor of the mouth is raised and tense.
Class III	when tongue is low in relation to mandibular ridge crest or retarded in relation to anterior ridge, retention of the mandibular denture will be poor.

Class 1 position has the most favorable prognosis as the floor of the tongue is at a higher level to cover the lingual flange of the denture producing a border seal. Whereas class II and III are unfavorable tongue positions as they drop

the level of floor of mouth hence providing an inadequate lingual seal and extension of flange resulting in overextension and dislodged denture at time of tongue movement. [12]

5. IMPORTANT ROLE OF TONGUE IN PROSTHETIC PROCEDURES

A) Tray selection

While seating the mandibular tray in position, the patient is asked to lift the tongue and bring it forward to avoid entrapping it below the tray.

The lingual borders of the tray are checked by functional movements of the tongue by bring the tongue straight out. If the tray rises vigorously from the posterior end, the distolingual flange could be overextended, thus has to be reduced.

Displacement of the tray when the tongue is moved to the right side would mean that the left side (mylohyoid portion) is overextended and vice versa. Displacement of the tray when the tongue is raised toward the soft palate could mean that the anterior portion or lingual frenum is overextended.

B) Border molding

Lingual frenum and sublingual flange- (premolar to premolar)

The patient is instructed to wipe his lower lip from side to side with the tongue tip and then asked to protrude the tongue to determines the height of the anterior lingual flange and records the frenum. Then the patient is asked to push his tongue forcefully against the front the front part of the palate to develop the thickness of the flange.

Mylohyoid portion

To mould the right lingual flange the patient is instructed to bring the tongue in contact with the left cheek and vice versa. This determines the length of the flange in this region. The flange in this region must slope towards the tongue to allow for the action of the mylohyoid.

Retro mylohyoid portion

Distal most part of the lingual flange which rises up towards the retromolar pad is limited by the retro mylohyoid curtain. The patient is asked to wide open the mouth, protrude the tongue and then close the jaw against resistance from the operators thumb.

C) Occlusal plane

The occlusal plane must lie at the lateral border of the tongue, if higher may result in unstable denture due to lateral tilting forces directed against the teeth.

D) Jaw relation

The mandibular wax rim and consequently the occlusal plane is at 2/3rd the height of the retromolar pad. The occlusal plane must lie at the lateral border of the tongue. While recording vertical relation the tongue must be in its normal position. While training the patient to close in centric, the patient may be asked to touch his tongue to the palate and swallow.

E) Teeth arrangement

The mylohyoid ridge is a reliable guide. The lingual cusps of the molars are aligned in harmony with the mylohyoid ridge, never lingual to it. Placing them far too lingually can cause: cramping of the tongue, tongue biting and instability of the denture during tongue function. Also, in order to balance the forces of the tongue pressing outwards with the forces of the cheeks and lips pressing inward, neutral zone technique was employed. Failure to recognize the importance of ideal tooth position, flange form and contour often results in dentures which are unstable and unsatisfactory while those in harmony with neuromuscular function are successful and stable dentures. [13,14]

F) Speech considerations

Sounds affected by the tongue can be the following: [15]

Linguo-dental: They are produced by the contacting the tip of the tongue against palatal surface of the upper anterior teeth. Eg:Th

Linguopalatal: They are produced by the tongue and palate. Eg: D,N,L,T.

Alveolar sounds: They are produced by the tongue placed against anterior portion of hard palate (D,T).

Nasal: (N, NG)

Excessive denture base thickness in palatal surface causes loss of tongue room and decreased volume of air. Expression of linguopalatal and linguoalveolar sounds may be difficult. If the teeth are placed far too lingually, or the arch is too narrow the tongue will be cramped resulting in faulty phonation, affecting linguoalveolar and lateral lingual sounds.

G) Polished surface contour

Martonet emphasized that the stability of lower denture depends upon the position of the tongue as it was considered to be a more powerful muscle than the lips and cheeks. [16] It exerts a force of 16.4 Psi [17], while the lips and cheeks exert only 4.3 Psi. [18] Therefore, when molding of the external contours was considered, the lingual surface

was the surface choice. Hence care must be taken while contouring the lingual surface as its influence can mitigate against stability.

H) Food trough formation and mastication

The opening and closing movements of the mandible during mastication is initiated by the neuromuscular movement of the tongue. [19] While mastication, some of the food may escape out from the premolar region and may fall into the buccal or lingual space which is then retrieved by the buccinator and the tongue, respectively. The fixation of the modiolus on the buccal surface of the lower first premolar initiates the posterior movement of food by the cheek along the tongue further facilitating deglutition.

6. DISCUSSION

Denture retention is the result of a number of different physical factors working in concert. The most significant are: adhesion, cohesion, intimate tissue contact, neuro-muscular control, hydrostatic pressure gradient, and border seal. One of the important neuromuscular contributions to denture retention and stability involves the tongue. [20]

The tongue is a multifunctional organ. In addition to assisting with MDR, Lee et al. reported that tongue contact with the anterior lingual flange of the mandibular denture is crucial to mandibular denture retention. [21]

Yoshikawa et al. reported that loss of occlusal support results in complex tongue-tip motion, and the absence of mandibular fixation may lead to tongue movement complexity. [22] Lidiane et al. reported that complete denture patients exhibit tongue thrust alternations in linguodental and alveolar phonemes to produce their sounds during speech. [23]

When patients transition from being dentate to edentulous, and then acquire complete dentures, additional functional demands are placed on the tongue. In addition to contributing to primary oral functions such as speech and mastication, the tongue is required to provide assistance with denture retention and stability.

7. CONCLUSION

Tongue is an integral part of the oral anatomy. Its nature as such in prosthodontics has been controversial due to its anatomy and action on the lower dentures. It is imperative that the prosthodontist have a proper knowledge of the anatomical, functional, physiologic aspects of the tongue so as to rehabilitate the patient to the optimum level possible with a retentive and stable denture.

REFERENCES

- Barnett, K.. (1995). An analysis of the tongue factors and its functioning areas in dental prosthesis. 5(5):629-35.
- Beresin, V.E., & Schiesser, F.J. (2006). The neutral zone in complete dentures. *J Prosthet Dent.* 95(2):93-100.
- Bohnenkamp, D.M., & Garcia, L.T. (2007). Phonetics and tongue position to improve mandibular denture retention. *J Pros Dent.* 98(5):344-7.
- Chaurasia's, B.D. (n.d.). *Human anatomy Vol 3, 4th edition*
- Dawson, P.E. (2017). *Functional Occlusion from TMJ to Smile Design.* St. Louis: Mosby.
- Jacobson, T.E., & Krol, A.J. (1983). A contemporary review of the factors involved in complete denture retention, stability, and support. Part I: retention. *J Prosthet Dent.* 49:5-15.
- Jacobson, T.E., & Krol A.J. (1983). A contemporary review of the factors involved in complete dentures. Part II: stability. *J Prosthet Dent.* 49:165-72.
- Jacobson, T.E., & Krol A.J. (1983). A contemporary review of the factors involved in complete dentures. Part III: support. *J Prosthet Dent.* 49:306-13.
- Kydd, W.L. (1957). Maximum forces exerted on the dentition by the perioral and lingual musculature. *J Am Dent Assoc.* 55(5):646-51.
- Lee, J.H., Chen, J.H., Lee, H.E., Chang, H.P., Chen, H.S., Yang, Y.H. et al. (2009). Improved denture retention in patients with retracted tongues. *J Am Dent Assoc* 2009, 140:987e91.
- Luthra, R.P., Renu, G., Savisha, N., Reena S., & Naresh, K. (2015). Neuromuscular system and complete dentures- A review. *Journal of Advanced Medical and Dental Sciences Research.* 3(4):113-6.
- Martonet, L. (1962). Clinical applications of concepts of functional anatomy and speech science to complete denture prosthodontics. Sept-Oct *J Prosthet Dent.* 12(5):817-34.
- Nadim, M.I, Bhattacharyya, I., M., & Cohen, D. (2011). Common Oral Manifestations of Systemic Disease. *Otolaryngol Clin N Am.* 44:161-182.
- Pala, A., Chowbey, R., Sonvanshi, N., Patel, D., Shah, A., & Venkatesh, A. (2016). A Review on Oral Manifestations of Systemic Diseases. *Int J Oral Health Med Res.* 2(6):131-132.
- Rajeshwari, K., Kohli, S., & Mathew, X.K. (2017). Evaluation of Resting Tongue Position in Recently Extracted and Long Term Completely Edentulous Patients: A Prospective Interventional Study. 11(4): ZC61-ZC63.

- Rinaldi, P., & Sharry, J. (1963). Tongue force and fatigue in adults. *J Prosthet Dent*. 13(5):857-65.
- Rodrigues, L.C., Pegoraro, L.F., Brasolotto, A.G., Berretin-Felix, G., & Genaro, K.F. (2010). Speech in different oral prosthetic rehabilitation modalities for elderly individuals. *Pro Fono*, 22:151e7.
- Rothman, R. (1961) Phonetics consideration in denture prosthesis. *J Prosthet Dent*. 11:214-23.
- Srinivas, K., Jyoti, G., Ratnakar, P., Sachdev, A. S., Saxena, V., & Taseer B. (2016). Anatomy of tongue - A review article. *International Journal of Multidisciplinary Research and Development*. 1(7):124-125.
- Winkler. (n.d.). *Essentials of complete denture prosthodontics - 3RD Edition*
- Wright, C.R. (2004) Evaluation of the factors necessary to develop stability in mandibular dentures. *J Prosthet Dent*. 92(6):509-18.
- Yoshikawa, M., Yoshida, M., Nagasaki, T., Tanimoto, K., Tsuga, K., & Akagawa, Y. (2008). Effect of tooth loss and denture wear on tongue- tip motion in elderly dentulous and edentulous people. *J Oral Rehabil*, 35:882e8.
- Zmudzski, J., Chladek, G., & Krawczyk, C. (2019). Relevance of tongue force on mandibular denture stabilization during mastication. *Journal of Prosth*. Vol 28 issue 1, e27-33